

Clinical application of HA-coated one-piece implants to the graftless procedure of immediate and early implant placement in the anterior maxilla

Yukiyasu Kishimoto

Abstract

Introduction: Inadequate alveolar bone volume is a common limitation for implantation in the anterior maxilla since bone resorption occurs soon after tooth extraction. Such problems have been overcome by bone grafting or GBR, however, these are invasive procedures and require a long treatment period.

Purpose: The aim of this study is to evaluate the efficacy of HA-coated one piece implants on the graftless procedure of immediate and early implant placement in the anterior maxilla.

Materials and methods: Thirty patients, 22 males and 8 females, 27 to 67 years of age, were included in this study. Thirty-four hydroxyapatite-coated one-piece implants (AQB implant®, ADVANCE, Co. Japan) were placed immediately or early within 8 weeks of tooth extraction. All implants were placed and positioned slightly towards the palatal aspect, leaving bone defects facially because the implants did not contact the facial aspects. In cases where bone chips were collected from the implant bed during drilling, they were placed on the facial aspect of the implant. No donor site was prepared. No membrane and filling materials were used. The following items were investigated. 1) Sex and age distribution, 2) Location of implants inserted, 3) Diameter and length of implants used, 4) Period from tooth extraction to implant placement, 5) Duration of the healing period from implant placement up to addition of occlusal force. The survey was carried from January 2005 through February 2013.

Results: All 34 implants were functionally loaded and showed no sign of morbidity and periimplant disease.

Conclusion: This retrospective study indicates that HA-coated one-piece implants are effective on the graftless procedure of immediate and early implant placement in the anterior maxilla. HA-coated one-piece implants may have the possibility of not only reducing donor site discomfort and morbidity, but also of shortening the treatment period.

1. Introduction

Recently, implant treatments have been used in an expanding number of situations. Bone resorption

occurs soon after tooth extraction, especially in the alveolar ridge of the anterior maxilla. In addition, the anterior sites are prominently visible and patients expect the implants to be esthetically pleasing, making implant placement challenging. Usually

implantation on the resorbed anterior maxilla has been achieved by the use of submerged implants following bone augmentation procedures such as bone transplantation and GBR, however, making the donor sites is an invasive procedure and time consuming. Therefore, it is desirable to have implantation without bone augmentation. In addition, when using submerged implants, bone resorption around the abutment-fixture interface (microgap) is common. The aim of this study is to evaluate the efficacy of HA-coated one-piece implants on the graftless procedure of immediate and early implant placement in the anterior maxilla.

2. Materials and Methods

Thirty patients, 22 males and 8 females, 27 to 67 years of age, were included in this study (Table 1). Thirty-four hydroxyapatite-coated one-piece implants made by the plasma spraying method and thermal decomposition technique (AQB implant®, ADVANCE Co. Japan) were placed immediately or early within 8 weeks of tooth extraction. All implants were inserted using both osteotomes and drills, and positioned slightly towards the palatal aspect, leaving bone defects facially because the implants did not contact the facial aspects. In cases where bone chips were collected from the implant bed during drilling, they were placed on the facial aspect of the implant. No donor site was prepared. No membrane and filling materials were used. The following items were investigated. 1) Sex and age distribution, 2) Location of implants inserted, 3) Diameter and length of implants used, 4) Period from tooth extraction to implant placement, 5) Duration of the healing period from implant placement up to addition of occlusal force (including acrylic provisional crown). The survey was carried from January 2005 through February 2013.

Table 1 : Sex and age distribution

age \ sex	Male	Female	Total
20-30	1	0	1
30-40	4	2	6
40-50	10	1	11
50-60	4	5	9
60-70	3	0	3
Total	22	8	30

3. Results

- 1) Out of the 34 implants, 17 (50.0%) were inserted in lateral incisors (Table 2).
- 2) The diameters of implants used were 4mm in 20 pieces (58.8%), and the length of implants used were 10mm in 18 pieces (52.9%) (Table 3).
- 3) Table 4 shows the period from tooth extraction to implant placement. Immediate placement was performed in 19 out of 34 pieces (55.9%).
- 4) The duration of the healing period from implant placement up to addition of occlusal force was 3 months or less in 12 pieces (35.3%), and 2 months or less in 8 pieces (23.5%) (Table 5). This data includes the establishment of occlusion by an acrylic provisional crown.

All 34 implants were functionally loaded and showed no signs of morbidity and periimplant disease.

Table 2 : Location of implants inserted

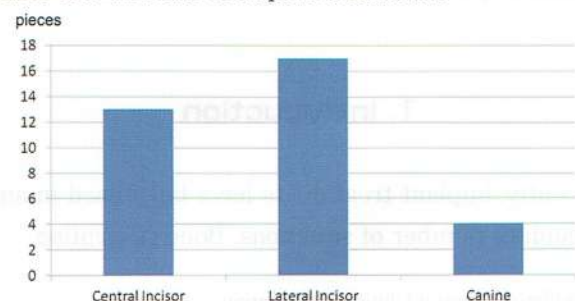


Table 3 : Diameter and length of implants used

length diameter	8mm	10mm	12mm	14mm	Total
3mm	1	10	0	1	12
4mm	10	6	4	0	20
5mm	0	2	0	0	2
Total	11	18	4	1	34

Table 4 : Period from tooth extraction to implant placement

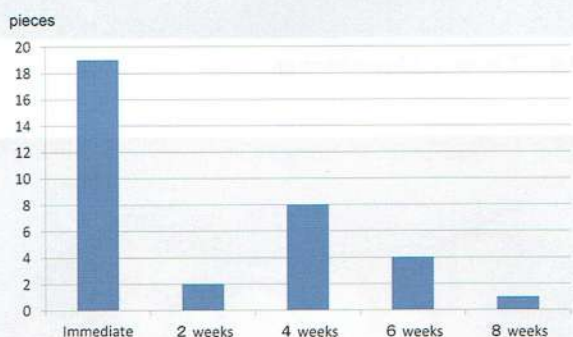
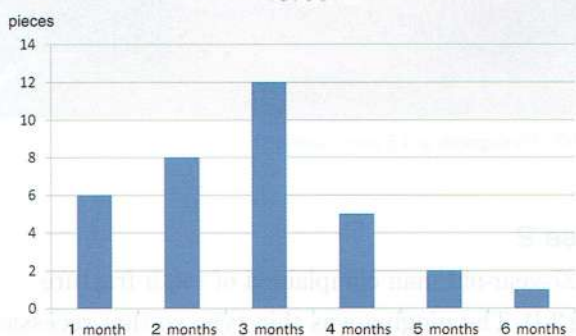

Table 5 : Duration of the healing period from implant placement up to addition of occlusal force



The typical 3 cases are presented below.

Case 1

A 30-year-old man came to our clinic for rehabilitation of his left lateral incisor maxilla (Fig.1-1). The intra-oral X-ray (Fig.1-2) taken revealed a large radicular cyst around the root's apex. This tooth was extracted and we evaluated whether the apex bone volume and quality was enough

for the implant's primary stability. Computed tomography was taken (Fig.1-3, Fig.1-4) for a definite diagnosis before implantation. Four weeks after tooth extraction, implantation without grafting was performed. The healing period was uneventful, 10 weeks later, a cemented porcelain-fused-to-metal crown was placed. At the 1.5-year follow-up, the implant was clinically stable. Newly formed bone was clearly visible around the implant neck and apex (Fig.1-5, Fig.1-6). The esthetic outcome was excellent (Fig.1-7).

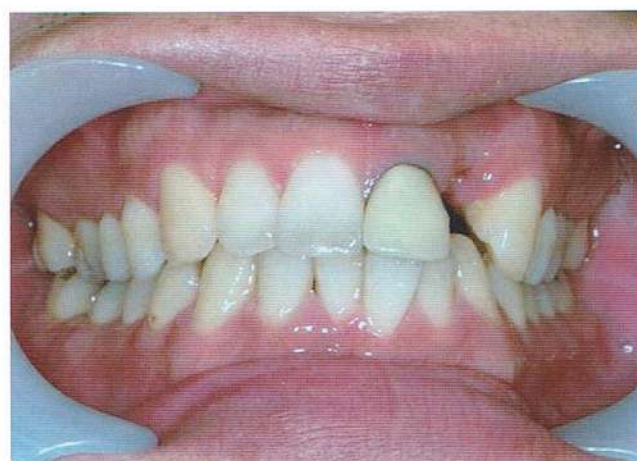

Fig.1-1 : Case1. Left lateral incisor. Clinical photograph before extraction

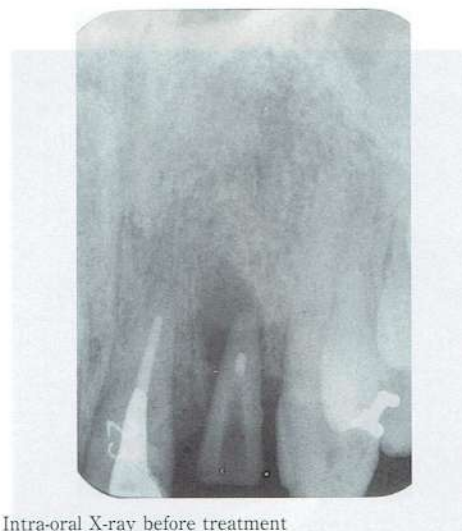

Fig.1-2 : Intra-oral X-ray before treatment

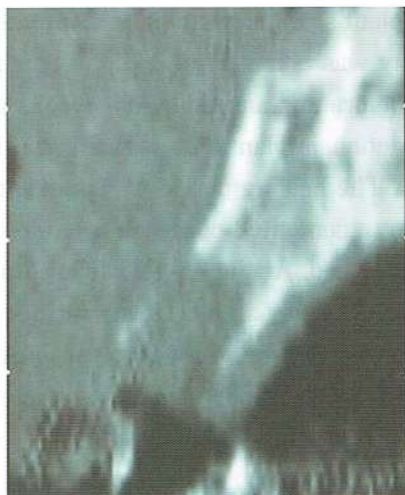


Fig.1-3 : CT image 3 weeks after extraction

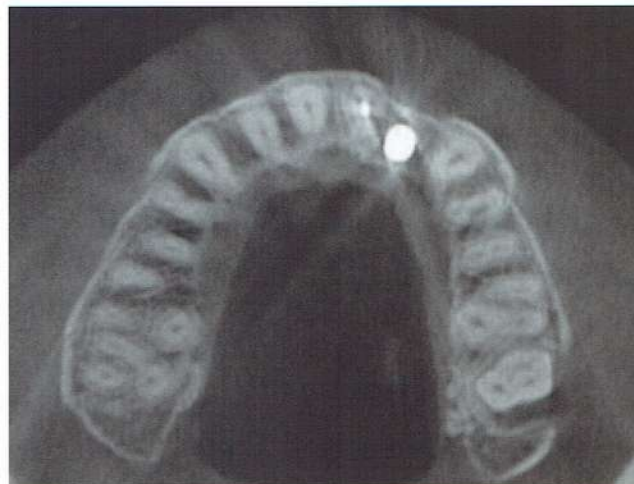

Fig 1-6 : CT image at 1.5-year follow-up

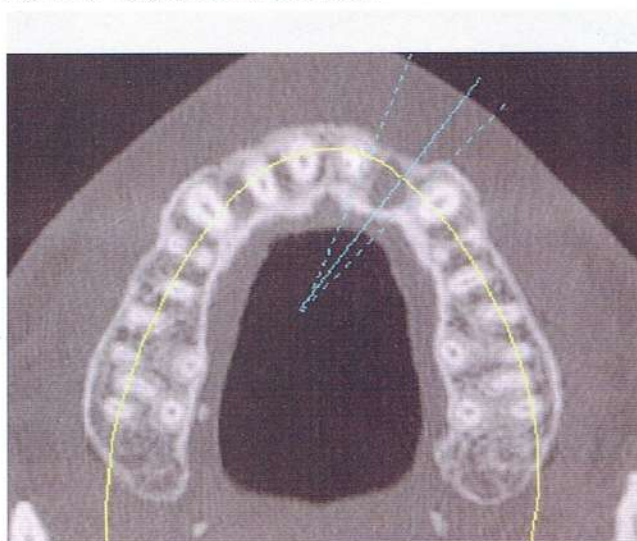


Fig.1-4 : CT image 3 weeks after extraction

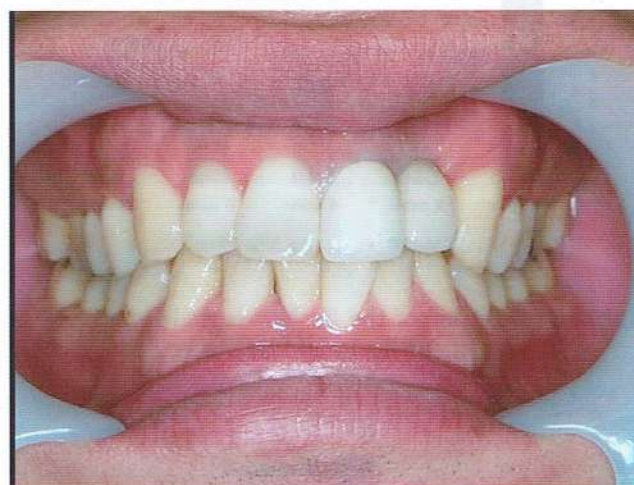

Fig 1-7 : Photograph at 1.5-year follow-up

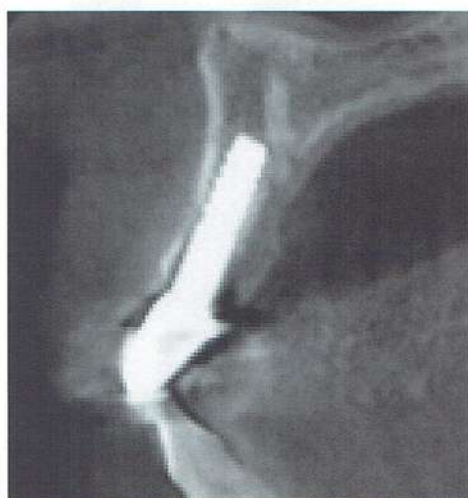

Fig.1-5 : CT image at 1.5-year follow-up

Case 2

A 27-year-old man complained of tooth fracture (Fig.2-1). The gingiva was thin type so that recession of the gingiva was expected following implantation. The intra-oral X-ray did not reveal any bone damage around his left lateral incisor. A porcelain-fused-to-metal crown was placed 8 weeks after immediate implant placement. The picture taken at the 1-year follow up showed good esthetic outcome without gingival recession (Fig.2-2). The computed tomography showed a thin buccal plate (Fig.2-3, Fig.2-4).

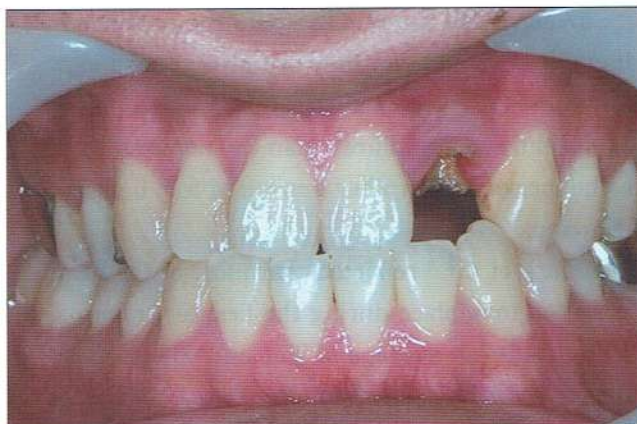

Fig.2-1 : Case2. Left lateral incisor. Clinical photograph before extraction

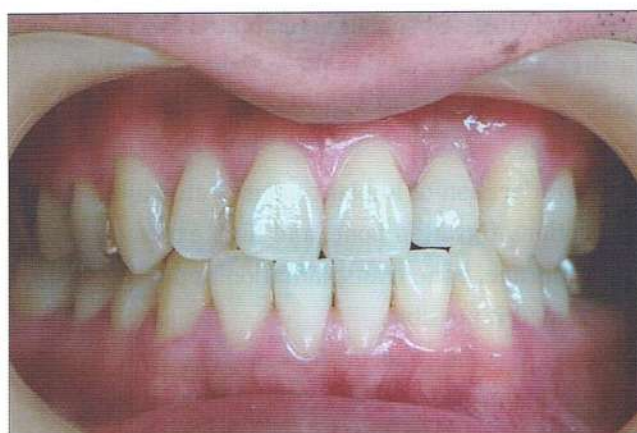

Fig 2-2 : Photograph at 1-year follow-up

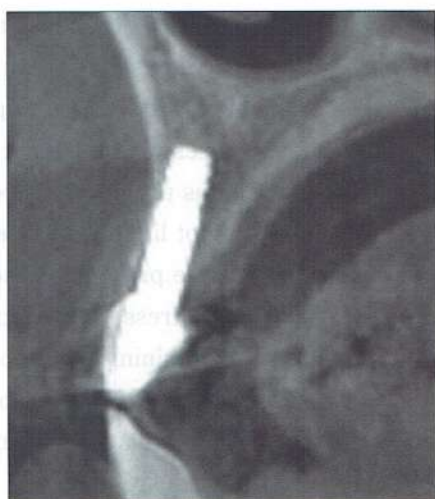

Fig 2-3 : CT image at 1-year follow up

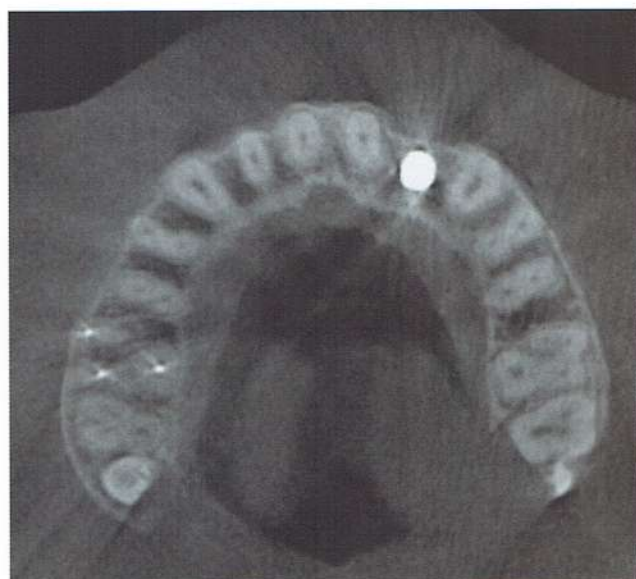


Fig 2-4 : CT image at 1-year follow up

Case 3

A 48-year-old man came to our clinic complaining of his tooth mobility. Recession of the facial gingiva was seen (Fig.3-1). Computed tomography showed severe bone resorption around his right central incisor (Fig.3-2). Immediate implant placement was performed, and final restoration was made 15 weeks after implantation. Creeping of facial gingiva was observed, and the patient's satisfaction was gained (Fig.3-3).

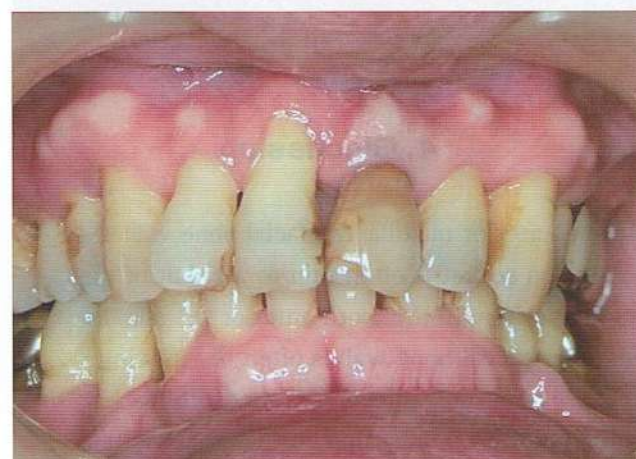

Fig 3-1 : Case3. Right central incisor.
Clinical photograph before extraction

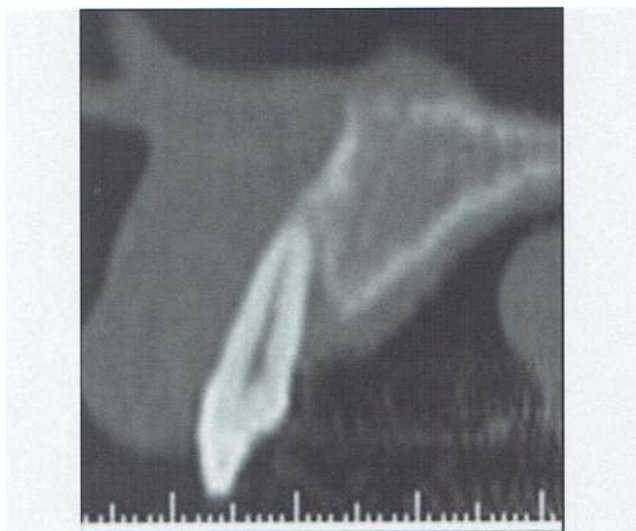

Fig 3-2 : CT image before extraction

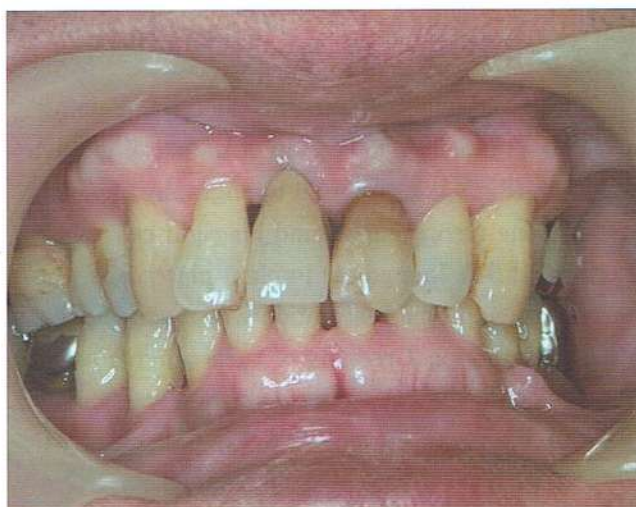

Fig 3-3 : Photograph at final restoration

4. Discussion

In the anterior maxilla, the facial bone wall of the extraction socket is often thin as a result of the buccal position of the tooth anterior maxilla. In addition, buccal bone wall is often be missing¹⁵⁾ because of chronic infection around the teeth to be extracted. Therefore, implantation in the anterior maxilla is sometimes challenging. Such problems replacing the teeth for dental implants have been overcome by bone transplantation, GBR, and using artificial bone. However, these procedures

are invasive and sometimes invite the patient's discomfort. In addition they are time consuming.

Becktor et al¹⁾ reported that the graft group had significantly more failures than the nongraft group in the incisor region after a mean of 5 to 6 years follow up.

Widmark et al^{2,3)} reported that most of the graft reduction took place during the first few months. In the study, an average of 25% and 60% of the graft volume was resorbed after 4 and 10 months respectively.

Nowzari et al⁵⁾ and Kohal et al⁶⁾ reported a high exposure rate of membrane used to regenerate peri-implant defects. The investigator assumed that in sites with exposed membrane, the amount of bone regenerated was less than sites with retained membrane.

In consideration of implant failures at grafted sites, resorption of grafted bone, and high exposure rate of membrane, bone transplantation and GBR should be avoided if possible.

There are some reports showing that osseointegration could be achieved immediately or early after extraction without grafting, either with or without the use of membrane^{4,7-11,16)}, and that the bone-to-implant gap could be filled with newly formed bone, preferably without the formation of fibrous tissue^{9,16)}. Although the use of the immediate and early implant placement without grafting was limited to being used for cases where only small bone defects were present, as previously reported^{8,17)}, the current study was not limited to cases where only small defects were present, as the case 1 demonstrated. Covani et al⁸⁾ stressed the importance of bony walls capable of maintaining a firm blood clot, and there is a report showing the possibility that osteoblast-lineage cells circulate more in the peripheral blood¹³⁾ than previously reported.

As for the bucco-lingual distance, Covani et al⁷⁾ reported that in cases of immediate placement without grafting, bucco-lingual distance of the alveolar crest reduced from 10.00 mm at the first

surgery to 8.10 mm at the second surgery, however, the data consisted of not only teeth in the anterior maxilla, but also of other kinds of teeth. Botticelli et al¹¹⁾ reported that following immediate implant placement, the horizontal resorption of the buccal bone dimension amounted to about 56%, and the corresponding resorption of lingual/palatal bone was 30%. This data also included teeth other than teeth from the anterior maxilla. Although the horizontal bone resorption of anterior maxilla following immediate and early implant placement is not well documented, more resorption is expected because buccal bone is thinner in the anterior maxilla than those in other sites.

In this study, Fig.1-6 showing the 1.5 year follow up after final prosthesis demonstrated that a very small amount of horizontal bone resorption occurred at the buccal site compared to Fig.1-4 before implant installation, however, the current study did not evaluate whether implant placement could prevent horizontal bone resorption following immediate and early implant placement.

There have been discussions about the esthetic outcomes of postextraction implants. Chen et al⁴⁾ and Buser et al¹²⁾ reported that recession of the facial mucosal margin is common in immediate implants. Early implant placement is associated with a lower frequency of mucosal recession compared to immediate placement.

Conversely, Covani et al¹⁴⁾ reported that the bone remodeling of implants placed in fresh extraction sockets without guided bone regeneration techniques showed the healing patterns associated with new bone apposition around the implants' neck. They stressed that although the vertical bone resorption has been observed at buccal sites in cases with immediate placement, it was not associated with any negative esthetic implications. In the case of the immediate implantation presented, Fig.2-2 at 1 year follow up did not show any esthetic implications as Covani et al¹⁴⁾ reported. They also

documented that no clinical differences between immediate and early implants without the use of membranes and filling materials, in terms of stability and complications, were observed throughout the investigation. Further, in cases with strong esthetic concerns, immediate implantation would be the procedure of choice⁷⁾. This study did not evaluate the clinical outcomes between immediate and early implant placement, however, cases presented in this study found no differences between them.

Kan et al¹⁷⁾ documented that using HA-coated implants without grafting could result in favorable implant success rates, peri-implant tissue response, and esthetic outcomes with immediately placed and provisionalized maxillary anterior single implants. They reported marginal bone loss at 1 year after immediate provisionalization were 0.22mm and 0.26mm at the mesial and distal aspects of the implants respectively, and they were smaller than the mean marginal bone loss of 0.93mm observed in implants loaded in the usual delayed protocol after the first year of function. Furthermore they reported that several implants placed immediately showed bone gain. They did not discuss whether this result came from using HA-coated implants or not.

It is well known bone resorption takes place around the implant interface (microgap) between the implant fixtures and the abutments. Bone resorption is considered to be caused by bacterial colonization among microgaps and micromovement of abutments¹⁸⁾. For making an implant bed in cases where submerged implants are applied, bone level of buccal sites and palatal sites must be the same height. If alveolar bone at the buccal site is resorbed, and an implant interface is deeply placed on the same level of the resorbed buccal alveolar bone, new bone resorption on the palatal site will proceed towards the implant interface which is located deep in the palatal alveolar crest. On the other hand, making an implant bed in cases where one-piece implants are applied, bone resorption does

not take place even if implants are deeply installed because they do not have microgaps. That is why one-piece implants, on the atrophic anterior maxilla, do not need to undergo bone augmentation.

5. Conclusion

This retrospective study indicates that HA-coated one-piece implants are effective on the graftless procedure of immediate and early implant placement in the anterior maxilla. HA-coated one-piece implants may have the possibility of reducing not only donor site discomfort and morbidity, but also of shortening treatment period. In addition, HA-coated one-piece implants may possibly accelerate osseointegration even though they are used on large bone defects.

References

- 1) Becktor JP, Isaksson S, et al.: Survival analysis of endosseous implants in grafted and nongrafted edentulous maxillae. *Int J Oral Maxillofac Implants* 19:107-115,2004.
- 2) Widmark G, Andersson B, et al.: Rehabilitation of patients with severely resorbed maxillae by means of implants with or without bone grafts:a 3- to 5-year follow up clinical report. *Int J Oral Maxillofac Implants* 16:73-79,2001.
- 3) Widmark G, Anderson B,et al.:Mandibular bone graft in the anterior maxilla for single tooth implants. Presentation of a surgical method. *Int J Oral Maxillofac Surg* 26:106-109,1997.
- 4) Chen ST, Buser D,et al.: Clinical and esthetic outcomes of implants placed in postextraction sites. *Int J Oral Maxillofac Implants* 24(suppl):186-217,2009.
- 5) Nowzari H, Slots J, et al. :Microbiologic and clinical study of polytetrafluoroethylene membranes for guided bone regeneration around implants. *Int J Oral Maxillofac Implants* 10: 67-73,1995.
- 6) Kohal RJ,Mellas P, et al.: The effects of guided bone regeneration and grafting on implants placed into immediate extraction sockets. An experimental study in dogs. *J Periodontol* 69:927-937,1998.
- 7) Covani U, Bortolaia C, et al. :Bucco-lingual crestal bone changes after immediate and delayed implant placement. *J Periodontol* 75:1605-1612,2004.
- 8) Covani U, Crespi R, et al. :Immediate implants supporting single crown restoration. A 4-year prospective study. *J Periodontol* 75:982-988,2004.
- 9) Paolantonio M, Dolci M, et al. :Immediate implantation in fresh extraction sockets. A controlled clinical and histological study in man. *J Periodontol* 72:1560-1571,2001
- 10) Wilson TGJ, Carnio J, et al.: Immediate implants covered with connective tissue membranes; human biopsies. *J Periodontol* 74:402-409,2003.
- 11) Botticelli D, Berglundh T, et al.: Hard-tissue alterations following immediate implant placement in extraction sites. *J Clin Periodontol* 31(10):820-828,2004.
- 12) Buser D, Wittneben J, et al.: Stability of contour augmentation and esthetic outcomes of implant-supported single crowns in the esthetic zone. 3-year results of a prospective study with early implant placement postextraction. *J Periodontol* 82: 342-349, 2011.
- 13) Guiti Z, Jesse L, et al.: Circulating osteoblast-lineage cells in humans. *N Engl J Med* 352:1959-1966,2005.
- 14) Covani U, Cornellini R, et al.: Vertical crestal bone changes around implants placed into fresh extraction sockets. *J Periodontol* 78:810-815,2007.
- 15) Myron N, Marcelo C, et al.: A study of the fate of the buccal wall of extraction sockets of teeth with prominent roots. *Int J Periodontics Restorative Dent* 26:19-29,2006.
- 16) Roberto C, Antonio S, et al. :Immediate one-stage postextraction implant. A human clinical and histologic case report. *Int J Oral Maxillofac Implants* 15:432-437,2000.
- 17) Kan J Y K, Rungcharassaeng K, et al.: Immediate placement and provisionalization of maxillary anterior single implants: 1-year prospective study. *Int J Oral Maxillofac Implants* 18: 31-39,2003.
- 18) Hermann J S, Schoolfield J D, et al.: Influence of the size of the microgap on crestal bone changes around titanium implants. A histometric evaluation of unloaded non-submerged implants in the canine mandible. *J Periodontol* 72:1372-1383,2001.